

Volume 1 Issue 1 2021

**INTERNATIONAL
JOURNAL OF
BIOLOGICAL AND
ENVIRONMENTAL
INVESTIGATIONS**

*Forum for Biological and
Environmental Sciences*

Published by Saran Publications, India



Prolactin induced cyto-architectural changes in the corpuscles of Stannius of stinging catfish, *Heteropneustes fossilis* acclimated to different calcium media

Srivastav Susmita¹, Mishra Diwakar², Kumar Abhishek³, Srivastav Sunil K.³, Suzuki Nobuo⁴ and Srivastav Ajai K.^{3*}

¹Department of Zoology, Shiv Harsh Kisan P. G. College, Basti-272001, India

²Department of Zoology, Government Girls' P. G. College, Ghazipur-233001, India

³Department of Zoology, D.D.U. Gorakhpur University, Gorakhpur-273009, India

⁴Noto Marine Laboratory, Institute of Nature and Environmental Technology, Kanazawa University, Noto-cho, Ishikawa 927-0553, Japan

*Corresponding author

Received: 9th April, 2021; Accepted: 25th May, 2021; Published online: 29th May, 2021

Abstract: Adult fish *Heteropneustes fossilis* were divided into 4 groups –(i) Group A: kept in artificial freshwater and daily injected intraperitoneally with vehicle; (ii) Group B: kept in artificial freshwater and were daily injected intraperitoneally with 0.1 mg/100 g body wt of oProlactin; (iii) Group C: maintained in calcium-deficient freshwater and daily injected intraperitoneally with vehicle; (iv) Group D: kept in calcium-deficient freshwater and daily injected intraperitoneally with 0.1 mg/100 g body wt of oProlactin. Blood samples were taken 2 h after the last injection on 1, 3, 5, 10 and 15 days of the treatment. Plasma calcium levels were analyzed. The corpuscles of Stannius (CS) were fixed for histological studies.

Artificial freshwater: The plasma calcium levels of vehicle-injected specimens (group A) remained unaltered throughout the experiment. Following prolactin treatment (group B) the plasma calcium levels progressively increased from day 3 to day 5. The values became normocalcemic at day 10 and day 15.

After day 5 following prolactin administration (group B), the nuclear volume of AF-positive cells increased and the cells were seen degranulated. After day 10, there was an increased dilatation of sinusoids and the nuclear volume of AF-positive cells showed further increase. On day 15, these changes were exaggerated. The AF-negative cells of the corpuscles of Stannius of prolactin-treated fish (group B) showed no change in their histological structure and nuclear volume.

Calcium-deficient freshwater: The plasma calcium level decreased in vehicle-injected fish (group C) from day 1 to day 3 (as compared to level of the fish kept in artificial freshwater). Thereafter, the level increased from day 5 resulting in hypercalcemia at day 10 and day 15. In prolactin treated fish (group D) the plasma calcium level indicated progressive increase from day 5 to day 15.

In the vehicle-injected fish (group C) the AF-positive cells of corpuscles of Stannius showed accumulation of granules between day 3 and day 5. The nuclear volume of these cells at these intervals exhibited no change. There was a slight decrease in the staining response of the cytoplasm of these cells after day 10 and day 15. The nuclear volume remained unaltered. The nuclear volume of AF-negative cells of vehicle-injected fish (group C) decreased between day 3 and day 5. However, the nuclear volume exhibited an increase on day 10 and day 15 thus approaching the normal values.

The AF-positive cells of CS of prolactin-treated fish (group D) exhibited no change up to day 3. After day 5, sinusoidal dilatation was noticed in the CS. Moreover, degranulation and increased nuclear volume of AF-positive cells were noticed. On day 10 and day 15, these changes were exaggerated. The AF-negative cells of prolactin-injected fish (group D) exhibited a progressive decrease in their nuclear volume from day 10 to day 15.

Keywords: Prolactin; Corpuscles of Stannius; Plasma calcium; *Heteropneustes fossilis*

Citation: Srivastav Susmita, Mishra Diwakar, Kumar Abhishek, Srivastav Sunil K., Suzuki Nobuo and Srivastav Ajai K.: Prolactin induced cyto-architectural changes in the corpuscles of Stannius to stinging catfish, *Heteropneustes fossilis* acclimated to different calcium media. Intern. J. Biol. Environ. Invest. 1 (1): 1-9, 2021. <https://doi.org/10.33745/ijbei.2021.v01i01.001>

Introduction

In vertebrates, calcium particularly ionic calcium, plays a vital role in a variety of biological processes therefore blood calcium levels are regulated precisely in vertebrates (Srivastav *et al.*, 2000, 2011; Srivastava *et al.*, 2021). This regulation is accomplished by calcium regulatory hormones acting mainly upon gut, bone and kidney. The endocrinal calcium regulation differ between aquatic and land vertebrates. Fish possess unique and more complex system than the terrestrial vertebrates as they (fish) are in constant contact with surrounding water (either freshwater or seawater) which provides an inexhaustible supply of calcium, thus in most cases facing considerable calcium gradients across the body surface. This situation is very much different in land vertebrates where direct exchanges of calcium between the body and surrounding medium are not possible and they have to rely solely on the food for calcium. In them calcium homeostasis is achieved mainly by a balance between intestinal calcium absorption and renal calcium excretion.

The regulation of calcium homeostasis in fishes involves a number of hormones secreted by different endocrine glands. The interplay of the (i) hypocalcemic factors- calcitonin (secreted by ultimobranchial gland) and Stanniocalcin (secreted by corpuscles of Stannius) and (ii) hypercalcemic factors- prolactin (by pituitary) and vitamin D metabolites at various target organs (skin, fin, gut, gill, bone, and kidney) is responsible for fish calcium homeostasis (Srivastav *et al.*, 2011).

The CS are encapsulated epithelial organs associated with the kidneys and are found exclusively in holostean and teleostean fishes (Wendelaar Bonga and Pang, 1986, 1991; Gu *et*

al., 2015). Stanniocalcin (the hormone secreted by corpuscles of Stannius) is a glycoprotein with a molecular radius that seems to vary slightly between species and that probably occurs in a liable dimeric form (Wendelaar Bonga and Pang, 1991). Several studies have implicated the corpuscles of Stannius in the control of calcemia in teleost fishes (Wendelaar Bonga and Pang, 1986, 1991; Srivastav *et al.*, 2011; Sivagurunathan *et al.*, 2020 a, b). There is a close relationship between the calcium concentration of the ambient water and the secretory activity of the type-1 (AF-positive) cells of the CS. Although the CS is found exclusively in the holostean and teleostean fishes, its hypocalcemic action has also been reported from non-piscine vertebrates - rat (Leung and Fenwick, 1978), parrot (Srivastav and Swarup, 1982a) and anurans (Pandey *et al.*, 1982). Few studies have also indicated that stanniocalcin is of wider occurrence than previously thought. Immunocytochemically stanniocalcin has been localized in the kidney of human and other mammals (Olsen *et al.*, 1996; de Niu *et al.*, 1998). Moreover, Zhang *et al.* (1998) have reported expression, purification, characterization and bioassay of human stanniocalcin. Worthington *et al.* (1999) have reported expression and localization of stanniocalcin 1 in rat bladder, kidney and ovary. Two mammalian Stanniocalcin genes -STC-1 and STC-2 have been reported to be expressed in various fish tissues as paracrine regulators (Luo *et al.*, 2005; Joshi, 2020). STC-1 has been reported in fish but now its presence has been confirmed in vertebrates and invertebrates (Ishibashi and Imai, 2002; Yoshiko and Aubin, 2004; Richards *et al.*, 2012; Palma *et al.*, 2019). Gu *et al.* (2015) reported three functional clusters and differential gene expression in the CS of fish adapted to freshwater and sea water. They have suggested

that CS is important for the regulation of ion homeostasis and blood pressure.

An attempt has been made in this study to investigate the effects of prolactin administration on the activity of calcium regulating endocrine gland- corpuscles of Stannius of the stinging catfish, *Heteropneustes fossilis* maintained either in artificial freshwater or calcium-deficient freshwater.

Materials and Methods

Adult fish *Heteropneustes fossilis* (both sexes; body wt 24-37 g) were procured and acclimatized to the laboratory conditions for two weeks. After acclimatization fish were divided into 4 numerically equal groups each containing 50 fishes. They were given following treatments:

Group A: Fish were maintained in artificial freshwater and were daily injected intraperitoneally daily with vehicle (0.1 ml of 0.6% NaCl/100 g body wt).

Group B: Fish were kept in artificial freshwater and were daily injected intraperitoneally with 0.1 mg/100 g body wt of oProlactin.

Group C: Fish were maintained in calcium-deficient freshwater and were daily injected intraperitoneally with vehicle.

Group D: Fish were kept in calcium-deficient freshwater and were daily injected intraperitoneally with 0.1 mg/100 g body wt of oProlactin.

Prolactin used in groups B and D was dissolved in 0.6% NaCl solution. Different artificial media i.e. freshwater and calcium-deficient freshwater were prepared as follows: (a) Artificial freshwater: Distilled water containing (in mmol/L): NaCl 2.10; Na₂SO₄ 0.45; KCl 0.06; CaCl₂ 0.8; MgCl₂ 0.20. pH of the solution was adjusted to 7.6 with NaHCO₃, (b) Calcium-deficient freshwater: same as artificial freshwater without CaCl₂.

Ten fish from each group were anaesthetized with MS 222 and blood samples were taken 2 h after the last injection on 1, 3, 5, 10 and 15 days of the treatment.

Blood samples were collected in heparinized tubes by sectioning of the caudal peduncle. The plasma were separated by centrifugation and analyzed for calcium levels by Sigma kits. After collection of blood samples the corpuscles of Stannius along with adjoining portion of kidney were removed and fixed in aqueous Bouin's fluid. Tissues were routinely processed in graded series of alcohols, cleared in xylene and embedded in paraffin. Serial sections were cut at 6 μm and stained with aldehyde fuchsin (AF) and hematoxylin-eosin (HE).

Nuclear (AF-positive and AF-negative cells of CS) indices (maximal length and maximal width) were taken with the aid of ocular micrometer and then nuclear volume was calculated as -
Volume = $4/3 \pi ab^2$

where 'a' is the major semiaxis and 'b' is the minor semiaxis.

Data are presented as the mean ± S.E. of six specimens. Student's t test was used to determine statistical significance. In all cases the experimental group was compared to its specific time control group.

Results

(A) Artificial Freshwater (Groups A and B):

No change was noticed in the plasma calcium levels of vehicle-injected specimens (group A; Fig. 1) throughout the experiment. Following prolactin treatment (group B) the plasma calcium levels remained unaffected on day 1. From day 3 to day 5 the levels progressively increased. The values became normocalcemic at day 10 and day 15 (Fig. 1).

The corpuscles of Stannius of vehicle-injected specimens (group A) *H. fossilis* exhibited two types of cells namely- AF-positive and AF-negative cells after staining with aldehyde fuchsin (Fig. 2). The gland depicted no change throughout the experiment.

Following 3 day prolactin treatment (group B), there was no change in the nuclear volume of corpuscular cells. After day 5, the nuclear volume of AF-positive cells recorded an increase

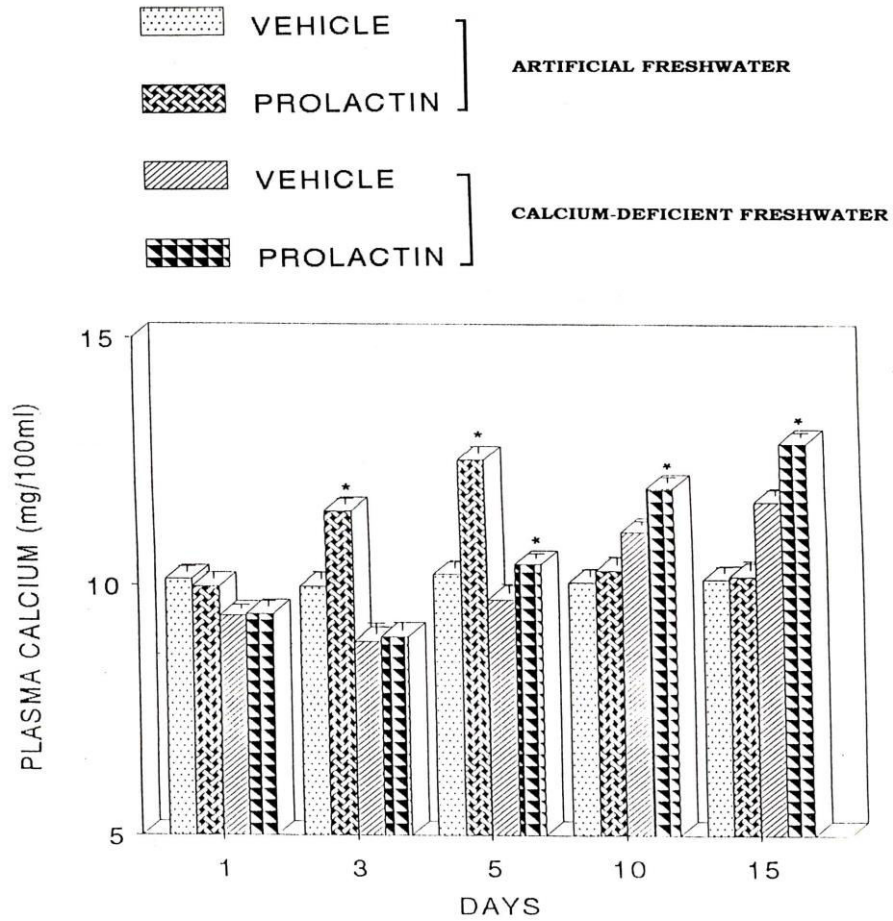


Fig. 1: Plasma calcium levels of *Heteropneustes fossilis* kept either in artificial freshwater or calcium-deficient freshwater and treated with vehicle or prolactin. Each value represents mean \pm S.E. of six specimens. Asterisk indicates significant differences ($P < 0.05$) with vehicle-injected specimens.

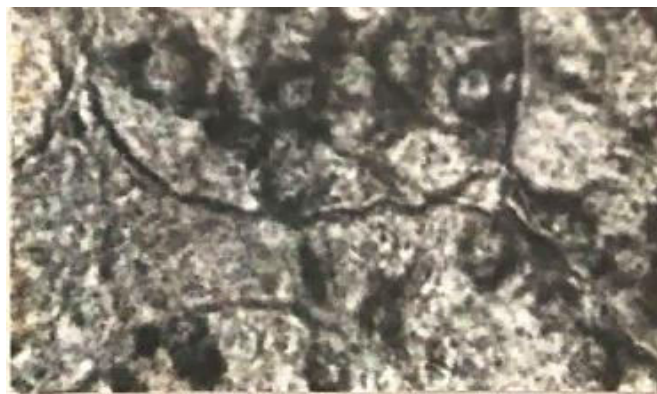

Fig. 2: Corpuscles of Stannius of 5 day vehicle-injected *Heteropneustes fossilis* kept in artificial freshwater depicting AF-positive and AF-negative cells. AF $\times 800$.

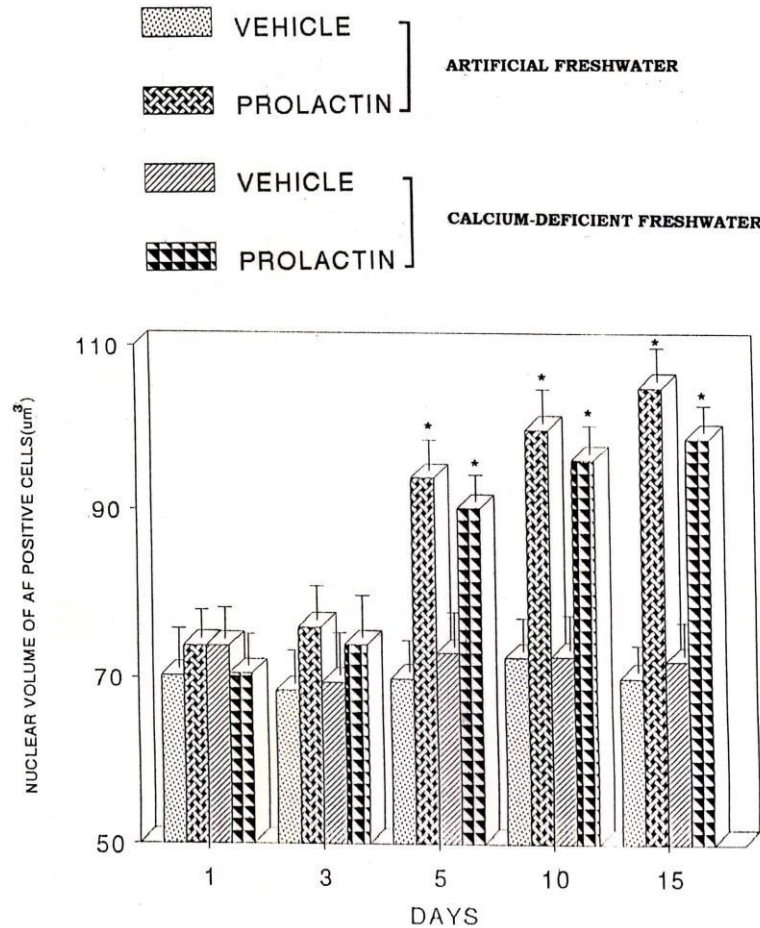


Fig. 3: Nuclear volume of AF-positive cells of CS of *Heteropneustes fossilis* kept either in artificial freshwater or calcium-deficient freshwater and treated with vehicle or prolactin. Each value represents mean \pm S.E. of six specimens. Asterisk indicates significant differences ($P < 0.05$) with vehicle-injected specimens.

(Fig. 3) and the cells were seen degranulated (Fig. 4). After day 10, there was an increased dilatation of sinusoids and the nuclear volume of AF-positive cells showed further increase (Fig. 3). On day 15, these changes were exaggerated (Fig. 3).

The AF-negative cells of the corpuscles of Stannius of prolactin-treated fish (group B) showed no change in their histological structure and nuclear volume (Fig. 5).

(B) *Calcium-deficient Freshwater (Groups C and D):*

In vehicle-injected fish (group C) the plasma calcium level decreased from day 1 to day 3 (as compared to level of the fish kept in artificial

freshwater). Thereafter, the level recorded an increase from day 5 resulting in hypercalcemia at day 10 and day 15 (Fig. 1). In prolactin treated fish (group D) the plasma calcium level showed no change up to day 3 as compared to the vehicle-injected group (group C). From day 5 to day 15, the plasma calcium level indicated progressive increase (Fig. 1).

In the vehicle-injected fish (group C) the AF-positive cells of corpuscles of Stannius showed accumulation of granules between day 3 and day 5 (Fig. 6). The nuclear volume of these cells at these intervals exhibited no change (Fig. 3). There was a slight decrease in the staining response of the cytoplasm of these cells after

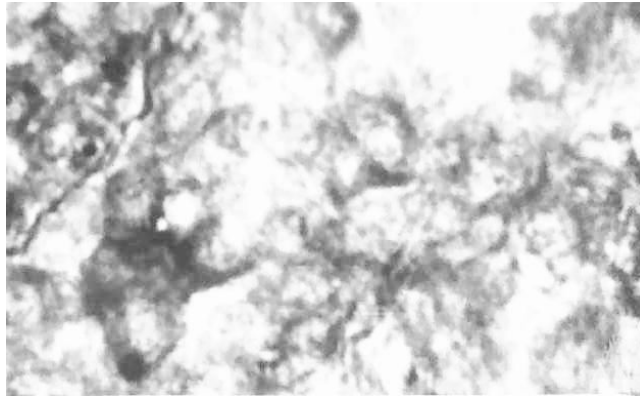


Fig. 4: Degranulation in the AF-positive cells of CS of 5 day prolactin treated fish kept in artificial freshwater. AF $\times 800$.

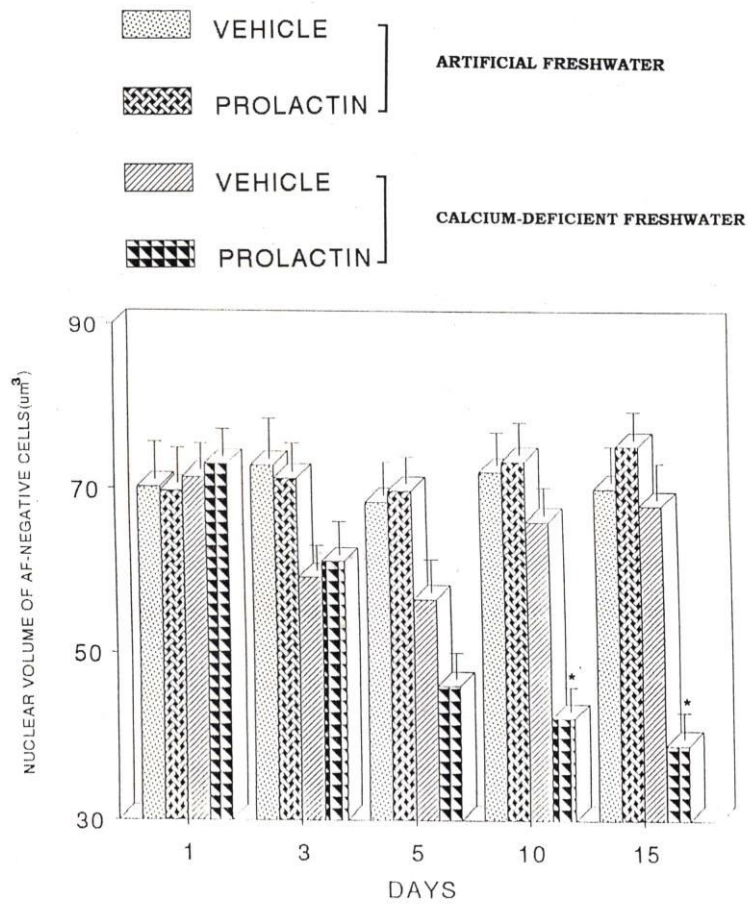


Fig. 5: Nuclear volume of AF-negative cells of CS of *Heteropneustes fossilis* kept either in artificial freshwater or calcium-deficient freshwater and treated with vehicle or prolactin. Each value represents mean \pm S.E. of six specimens. Asterisk indicates significant differences ($P < 0.05$) with vehicle-injected specimens.

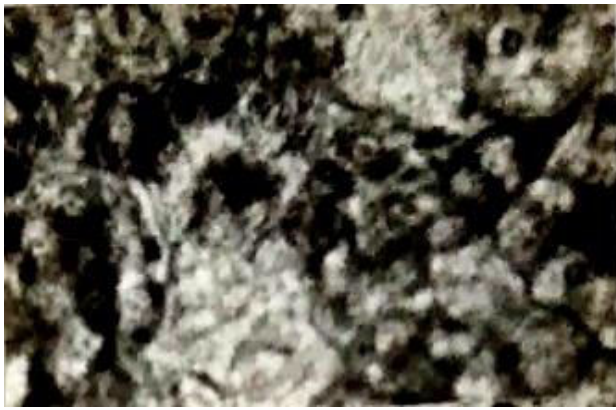

Fig. 6: Increased granules in the AF-positive cells of CS of 3 day vehicle-injected fish kept in calcium-deficient freshwater. AF \times 800.



Fig. 7: Slight degranulation in the AF-positive cells of CS of 10 day vehicle-injected fish kept in calcium-deficient freshwater. AF \times 800.

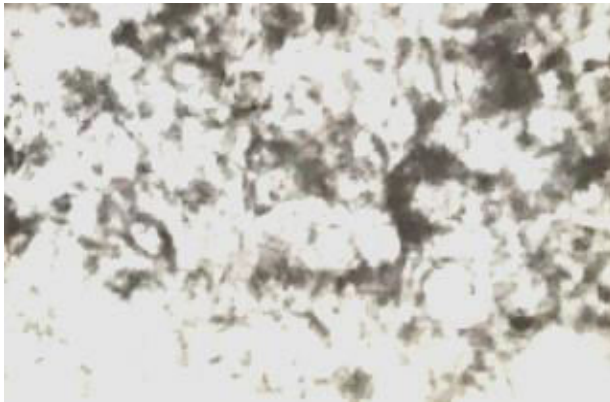


Fig. 8: Degranulation of AF-positive cells of CS of 5 day prolactin treated fish kept in calcium-deficient freshwater. AF \times 800.

day 10 and day 15 (Fig. 7). The nuclear volume remained unaltered (Fig. 3).

There was no change in the nuclear volume of AF-negative cells of vehicle-injected fish

(group C) after day 1. A decrease in the nuclear volume was recorded between day 3 and day 5 (Fig. 5). However, the nuclear volume exhibited an increase on day 10 and day 15 thus approaching the normal values (Fig. 5).

The AF-positive cells of CS of prolactin-treated fish (group D) showed no change up to day 3. After day 5, sinusoidal dilatation was noticed in the CS. Moreover, degranulation (Fig. 8) and increased nuclear volume (Fig. 3) of AF-positive cells were noticed. On day 10 and day 15, these changes were exaggerated (Fig. 3).

The AF-negative cells of prolactin-injected fish (group D) exhibited a progressive decrease in their nuclear volume from day 10 to day 15 (Fig. 5).

Discussion

In calcium-deficient freshwater the CS of vehicle-injected *H. fossilis* exhibit an accumulation of AF-positive granules which may be due to observed hypocalcemia. Wendelaar Bonga *et al.* (1980) have noticed hypoactive type-1 cells in the fish exposed to low-calcium seawater. Accumulation of secretory granules in the AF-positive cells has also been reported in the fish kept in calcium-deficient freshwater (Tiwari, 1993; Singh and Srivastav, 1996). Hypocalcemia has also been reported to cause storage of secretory granules in the calcitonin cells (which is responsible for secreting a hypocalcemic hormone) in mammals (Gittes *et al.*, 1968; Leitz and Donath, 1970; Biddulph and Maibenco, 1972; Swarup *et al.*, 1980; Srivastav and Swarup, 1982 b). Hirsch and Munson (1969) have reported that the heavy accumulation of secretory granules in mammalian calcitonin cells during hypocalcemia results due to little or no calcitonin secretion and continuance of its biosynthesis. The same principle seems to be involved in the present study also.

Prolactin administration to the fish *H. fossilis* kept either in artificial freshwater or calcium-deficient freshwater caused increased nuclear volume of AF-positive cells. Hypertrophy of corpuscular cells has been considered by various

investigators (Cohen *et al.*, 1975; Wendelaar Bonga *et al.*, 1976; Olivereau and Olivereau, 1978; Srivastav and Srivastav, 1988; Tiwari, 1993; Singh and Srivastav, 1996; Srivastav *et al.*, 2016; Sivagurunathan *et al.*, 2020 a, b) as an indication of the activity of CS in response to increased blood calcium levels. AF-positive cells of the CS of prolactin-injected fish kept either in artificial freshwater or calcium-deficient freshwater exhibited degranulation. In past similar response of these cells has also been reported by Aida *et al.* (1980), Srivastav *et al.* (1985), Tiwari (1993) and Singh and Srivastav (1996).

The AF-negative cells of CS exhibit a decrease in the nuclear volume when the fish were kept in calcium-deficient freshwater. This reduced activity of AF-negative (type-2) cells in calcium-deficient freshwater may be attributed to the possible increase in the plasma sodium level as it has been reported that removal of calcium from the water bathing the gills of gold fish resulted in a two-fold increase in Na⁺ influx (Cuthbert and Maetz, 1972).

Acknowledgment

The authors are thankful to the Head, Department of Zoology, D. D. U. Gorakhpur University, Gorakhpur, India, for providing laboratory facilities for this study.

References

Aida K, Nishioka RS and Bern HA. (1980) Degranulation of the Stannius corpuscles of coho salmon (*Oncorhynchus kisitch*) in response to ionic changes in vitro. *Gen Comp Endocrinol.* 41: 305-313.

Biddulph DM and Maibenco HC. (1972) Response of hamster thyroid light cells to plasma calcium. *Anat Rec.* 173: 25-43.

Cohen RS, Pang PKT and Clark NB. (1975) Ultrastructure of the Stannius corpuscles of the killifish, *Fundulus heteroclitus* and its relation to calcium regulation. *Gen Comp Endocrinol.* 27: 414-423.

Cuthbert HW and Maetz J. (1972) The effects of calcium and magnesium and sodium fluxes through gills of *Carassius auratus*. *J Physiol.* 221: 633-643.

de Niu P, Olsen HS, Gentz R and Wagner GF. (1998) Immunolocalization of stanniocalcin in human kidney. *Mol Cell Endocrinol.* 137: 155-159.

Gittes RF, Toverud SV and Cooper CW. (1968) Effects of hypercalcemia and hypocalcemia on the thyrocalcitonin content of rat thyroid glands. *Endocrinology* 82: 83-90.

Gu Jie, Jing-Woei Li, William, Ka-Fai Tse, Ting-Fung Chan, Keng-Po Lai and Chris Kong-Chu W. (2015) Transcriptomic responses of corpuscle of Stannius gland of Japanese eels (*Anguilla japonica*) to changes in water salinity. *Sci Rep.* 5: 9836. <https://doi.org/10.1038/srep09836>.

Hirsch PF and Munson PL. (1969) Thyrocalcitonin. *Physiol Rev.* 49: 548-622.

Ishibashi K and Imai M. (2002) Prospect of a Stanniocalcin endocrine/paracrine system in mammals. *Am J Physiol Renal Physiol.* 282: F367-F375.

Joshi AD. (2020) New insights in to physiological and pathophysiological functions of stanniocalcin-2. *Frontiers Endocrinol.* 11 (172): 1-8.

Leitz H and Donath K. (1970) Cytochemical evidence for the presence of hormonal peptides in thyroid C cells. In *Calcitonin 1969*, (ed.) Taylor, S., Proc. 2nd Intern. Symp. London, William Heinemann Medical Books Ltd., London, pp. 227-239.

Leung E and Fenwick JC. (1978) Hypocalcemic asction of eel Stannius corpuscles in rats. *Can J Zool.* 56: 2333-2335.

Luo CW, Pisarska MD and Aaron JWH. (2005) Identification of a stanniocalcin paralog, stanniocalcin-2, in fish and the paracrine actions of stanniocalcin-2 in the mammalian ovary. *Endocrinology* 146(1): 469-476.

Olivereau M and Olivereau J. (1978) Prolactin, hypercalcemia and corpuscles of Stannius in seawater eels. *Cell Tissue Res.* 186: 81-96.

Olsen HS, Rosen CA, Vozzolo BL, Jaworski EM and Wagner GF. (1996) Human stanniocalcin: a possible hormonal regulator of mineral metabolism. *Proc Natl Acad Sci USA.* 93: 1792-1796.

Palma PFS, Bock C, Silva TS, Guerreiro PM, Power DM, Pörtner Hans-Otto and Canário AVM. (2019) STC1 and PTHrP modify carbohydrate and lipid metabolism in liver of a teleost fish. *Sci Rep.* 9(723): 1-12.

Pandey AK, Krishna L, Srivastav Ajai K and Swarup K. (1982) Response of serum calcium to administration of an extract from Stannius corpuscles in the anurans. *Experientia* 38: 314-315.

- Richards TDJ, Fenton AL, Syed R and Wagner GF. (2012) Characterization of stanniocalcin-receptors in the rainbow trout. *ISRN Endocrinol.* 2012: doi:10.5402/2012/257841.
- Singh S and Srivastav Ajai K. (1996) Vitamin D₃ induced histological changes in the corpuscles of Stannius of a freshwater catfish, *Heteropneustes fossilis* kept either in artificial freshwater, calcium-rich freshwater or calcium-deficient freshwater. *Okajimas Folia Anat Jap.* 73: 75-82.
- Sivagurunathan U, Srivastava PP, Gupta S and Gopal K. (2020a) Responses of corpuscles of Stannius to intra-peritoneal vitamin-D₃ administration in teleost *Labeo rohita* (Hamilton, 1822) reared in water with two different levels of calcium concentration. *Saudi J Biol Sci.* 27: 3593-3600.
- Sivagurunathan U, Srivastava PP and Subodh G. (2020 b) Vitamin-D₃ induced changes in the corpuscles of Stannius gland of *Labeo rohita* (Hamilton, 1822), reared in low, and high calcium-rich water. *J Applied Biol Sci.* 14: 240-248.
- Srivastav Ajai K, Das VK, Srivastav SK and Suzuki N. (2000) Amphibian calcium regulation: physiological aspects. *Zool Polon.* 45: 7-26.
- Srivastav Ajai K, Das VK, Srivastav SK and Kumar A. (2011) Environmental contaminants: Impact on endocrinal calcium regulation in fish. In: *Emerging trends in Zoology*, (eds.) Srivastava U.C. and Kumar S., Narendra Publishing House, India, pp. 319-334.
- Srivastav Ajai K, Singh S and Sasayama Y. (1995) Vitamin D₃ induced changes in the prolactin cells of the fish, *Heteropneustes fossilis* reared in artificial freshwater, calcium-rich freshwater or calcium-deficient freshwater. *J Reprod Biol Comp Endocrinol.* 7: 72-82.
- Srivastav Ajai K and Srivastav SP. (1988) Corpuscles of Stannius of *Clarias batrachus* in response to 1,25 dihydroxyvitamin D₃ administration. *Zool Sci.* 5: 197-200.
- Srivastav Ajai K and Swarup K. (1982a) Calcemic responses of Stannius corpuscles extract in parrots, *Psittacula psittacula*. *Experientia* 38: 869.
- Srivastav Ajai K and Swarup K. (1982b) Effects of calcitonin on calcitonin cells, parathyroid glands and serum electrolytes in the house shrew *Suncus murinus*. *Acta anat.* 114:81-87.
- Srivastav S, Mishra D, Srivastav SK and Srivastav Ajai K. (2016) Alterations in the corpuscles of Stannius after estradiol administration to stinging fish, *Heteropneustes fossilis* maintained in different calcium environments. *Intern J Zool Invest.* 2: 24-34.
- Srivastava BD, Srivastava M, Srivastav SK, Urata M, Suzuki N and Srivastav Ajai K. (2021) Ameliorative effects of jamun seed and orange peel extracts on microcystin LR induced alterations in calcitonin cells and parathyroid gland of rats. *Micros Res Tech.* 84: 571-578.
- Swarup K, Tewari NP and Srivastav Ajai K. (1980) Response of calcitonin cells, parathyroid glands and bone to prolonged calcitonin administration in the Indian palm squirrel *Funambulus pennanti* (Wroughton). *Acta anat.* 106: 180-191.
- Tiwari PR. (1993) Endocrinal regulation of calcium in teleost. Ph.D. Thesis, University of Gorakhpur, Gorakhpur, India.
- Wendelaar Bonga SE. (1980) Effect of synthetic salmon calcitonin and low ambient calcium on plasma calcium, ultimobranchial cells, Stannius bodies and prolactin cells in the teleost *Gasterosteus aculeatus*. *Gen Comp Endocrinol.* 40: 99-108.
- Wendelaar Bonga SE, Greven JAA and Veenhuis M. (1976) The relationship between ionic composition of the environment and secretory activity of the endocrine cell types of Stannius corpuscles in the teleost *Gasterosteus aculeatus*. *Cell Tissue Res.* 175: 297-312.
- Wendelaar Bonga SE and Pang PKT. (1986) Stannius corpuscles. In: *Vertebrate Endocrinology: Fundamentals and Biomedical Implications*, (eds.) Pang, P.K.T. and Schreibman, M.P., vol. 1, Academic Press, London, pp. 436-464.
- Wendelaar Bonga SE and Pang PKT. (1991) Control of calcium regulating hormones in the vertebrates: Parathyroid hormone, calcitonin, prolactin and stanniocalcin. *Int Rev Cytol.* 128: 139-213.
- Worthington RA, Brown L, Jellinek D, Chang AC, Reddel RR, Hambly BD and Barden JA. (1999) Expression and localization of stanniocalcin 1 in rat bladder, kidney and ovary. *Electrophor.* 20: 2071-2076.
- Yoshiko Y and Aubin JE. (2004) Stanniocalcin 1 as a pleiotropic factor in mammals. *Peptides* 25(10): 1663-1669.
- Zhang J, Alfonso P, Thotakura NR, Su J, Buergin M, Parmelee D, Collins AW, Oelkuct M, Gaffney S, Gentz S, Radman DP, Wagner GF and Gentz R. (1998) Expression, purification, and bioassay of human stanniocalcin from baculovirus-infected insect cells and recombinant CHO cells. *Protein Expr Purif.* 12: 390-398.